

Clinical Effects on Skin Texture and Hydration of the Face Using Microbotox and Microhyaluronicacid

JongSeo Kim, MD

Background: Improving skin texture in the face is a popular procedure in older women. Procedures using stabilized hyaluronic acid (S-HA) to improve skin texture should be distinguished from volumizing procedures. The intradermal injection of S-HA has many benefits, such as being safe from embolism, having a high ease of injection, and leading to dramatic improvements in skin texture and hydration. HA is the main component of the extracellular matrix and dermal hydration can help counteract the effects of aging. When the dermis is well hydrated using S-HA, it looks healthier, and this effect can last for more than half a year. Various intradermal injection techniques have been reported, such as manual injection, the blanching technique, and using an automatic injector with multiple needles.

Method: The dermis can be treated with microdroplets (0.001 cc) of S-HA at a thousand of injection sites using an injector. This unique injection method was Named "Microhyaluronicacid" by the author, based on an analogy with Microbotox⁵. The author invented a unique injection solution in which S-HA is mixed with botulinum toxin A; this solution has been used for dermal hydration and skin rejuvenation since 2009. To reduce the risk of creating a dermal lump, polydensified monophasic HA and automatic injector were used. Microhyaluronicacid and Microbotox were combined by the author.

Results: In 50 patients, changes in fine wrinkles were measured using a dermascope, and dermal hydration was measured by transepidermal water loss and stratum corneum hydration levels.

Conclusion: The changes of transepidermal water loss and stratum corneum hydration were statically significant at 4 and 8 weeks. (*Plast Reconstr Surg Glob Open* 2018;6:e1935; doi: 10.1097/GOX.0000000000001935; Published online 12 November 2018.)

INTRODUCTION

Improving skin texture in the face is a popular procedure in older women. Procedures using stabilized hyaluronic acid (S-HA) to improve skin texture should be distinguished from volumizing procedures.¹ The intradermal injection of S-HA has many benefits, such as being safe from embolism, being easy to inject, and leading to dramatic improvements in skin texture and hydration.² HA is the main component of the extracellular matrix (ECM) and dermal hydration can help counteract the effects of aging. When the dermis is well hydrated using S-HA, it looks healthier, and this effect can last for more than half a year.^{1,2} Various intrader-

mal injection techniques have been reported, such as manual injection,³ the blanching technique,⁴ and automatic injector using multiple needles.² The dermis can be treated with microdroplets (0.001 cc) of S-HA at a thousand of injection sites using an automatic injector. This unique injection method was named "Microhyaluronicacid" by the author, based on an analogy with Microbotox.⁵ Microhyaluronicacid and Microbotox were combined by the author. The author invented a unique injection solution in which S-HA is mixed with botulinum toxin A; this solution has been used for dermal hydration and skin rejuvenation since 2009.^{1,2} To reduce the risk of creating a dermal lump, polydensified monophasic HA and automatic injector were used. In 50 patients, changes in fine wrinkles were measured using a dermascope, and dermal hydration was measured

From the Plastic Surgery Clinic, Seoul, Korea.

Received for publication May 15, 2018; accepted July 18, 2018.

Copyright © 2018 The Author. Published by Wolters Kluwer Health, Inc. on behalf of The American Society of Plastic Surgeons. This is an open-access article distributed under the terms of the Creative Commons Attribution-Non Commercial-No Derivatives License 4.0 (CCBY-NC-ND), where it is permissible to download and share the work provided it is properly cited. The work cannot be changed in any way or used commercially without permission from the journal.

DOI: 10.1097/GOX.0000000000001935

Disclosure: The author has no financial interest to declare in relation to the content of this article. The Article Processing Charge was paid for by the author.

Supplemental digital content is available for this article. Clickable URL citations appear in the text.

by transepidermal water loss (TEWL) and stratum corneum hydration (SCH) levels.

PATIENTS AND METHODS

The study was a single-center, prospective, in vivo study with dermal injections using a unique mixture of S-HA and botulinum toxin A. From January 2014 to December 2016, 50 women (age range, 31–65 years; average age, 49.8 years) with fine wrinkles and subjective signs of dryness on the face (especially forehead, around the eyelid, and the upper lip) participated in the study. All subjects had been treated with only botulinum toxin in the past (more than 6 months ago) at the author's clinic and were familiar with the injection processes associated with Microbotox.⁵ The intradermal injection method of S-HA using an injector (Microhyaluronic acid) was already approved by the Korean Intellectual Property Office as a patented technology.⁶ Informed consent was obtained from each patient about Microhyaluronic acid and Microbotox, and the study adhered to the tenets of the Declaration of Helsinki. All patients received intradermal injections and were observed to assess (1) changes in the appearance of the facial skin; (2) changes in dermatoscopic findings; and (3) SCH and TEWL values. Subjects were to adhere to their usual skin care routine for 8 weeks before and 6 months after the injections. The subjects who had procedures such as HIFU (Unthera) or RF (Thermage) within 1 year before and after the injection were excluded.

Injection Method

Before the treatment, patients were first prepared with a layer of 9% lidocaine topical anesthetic cream and covered with plastic wrap as occlusive draping to facilitate the infiltration of anesthetic materials into the dermis. After 30 minutes, this was thoroughly washed off.

For reconstitution of the injection material, 1 cc of polydensified monophasic HA (Belotero Balance; Anteis, Geneva, Switzerland, and distributed by Merz Pharmaceuticals) was mixed with 1 cc (40 U) of incobotulinum toxin A (Xeomin, Merz Pharmaceuticals, Germany) and 1 cc of normal saline. This mixture of Belotero and Xeomin was named the "XeoBel hydrotoxin" solution and can be used in a single session for Microbotox and Microhyaluronic acid procedures. During the reconstitution, it is very important to ensure that no air bubbles are present in a 3-cc syringe without forming air bubbles passing 30 times through connector and two 3-cc syringes, because air bubbles collapse with the pressure of the injection and can disturb or delay the injection. In this procedure, 3 cc of the XeoBel mixture was injected in 990 sites on the face. Therefore, the amount of toxin was approximately 0.04 U, and the amount of S-HA was 0.001 cc per injection site. An automatic injector (XeoBel-injector; Contac-Korea, Seoul, Korea) was used to inject the solution into the dermis. The injector ensured the depth was intradermis with 0.001 c of amount for all patients. The depth of the injector was set at 1 mm, and the actual injection depth was approximately 0.8 mm due to bevel on the needle tip.⁵ This device has nine 32-gauge needles, which were distributed in a way that provided a regular distance (3.5 mm) between the in-

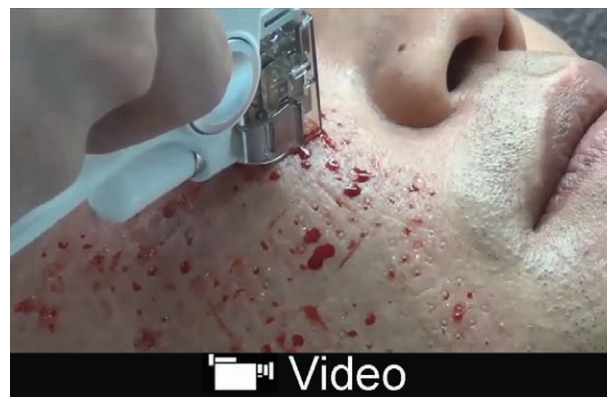jections of Microbotox and Microhyaluronic acid throughout the face (see video, **Supplementary Digital Content 1**, which displays the injection method that does not create lumps after injecting S-HA to the dermis: which includes (1) monophasic HA; (2) lessened injection amount per site; and (3) dilution. This video is available in the "Related Videos" section of the Full-Text article at PRSGlobalOpen.com or at <http://links.lww.com/PRSGO/A861>).

If the solution is too easily injected and a leaking sound can be heard, the needle has most likely been inserted too superficially. If a leaking sound occurred, the injection depth was increased by 0.2 mm.⁵ Whereas more bleeding means that the injection depth is too deep under the dermis. If substantial bleeding was noted, the injection was considered to have penetrated the subdermal plexus. With good injection technique and optimal injection depth into the dermis, there is less bleeding and ecchymosis and the possibility of injecting too much in a single location diminished. Very small raised lumps or blanched blebs in the skin should be seen after an intradermal injection (Fig. 1), and these are normal due to the depth of the injection. These lumps disappeared the following day. To reduce dermal lumps, polydensified HA was used because it has a high spreading property and it can integrate with the skin.⁷

At the end of the procedure, ice cooling and compression were applied on the face to relieve pain and to facilitate in the spread of dermal lumps. Thin skin, such as the lower eyelid, lumps can easily develop, and these lumps should immediately be spread out by compression with a cotton ball or massage (see video, **Supplementary Digital Content 1**).

Skin Roughness and Morphology

Skin roughness and morphology were evaluated using 5 levels (1: very smooth, 2: smooth, 3: moderate, 4: rough, and 5: very rough) at 2, 4, and 8 weeks using a noncontact method with a dermatoscope ($\times 10$, $\times 50$ resolution, Coscam, Sometch, Korea) on the forehead (2 cm above the right eyebrow on the vertical pupil line) and crow's feet area (2 cm lateral to and 2 cm below the right lateral canthus).



Video Graphic 1. See video, **Supplementary Digital Content 1**, which displays the injection method that does not create lumps after injecting S-HA to the dermis: which includes (1) monophasic HA, (2) lessened injection amount per site, and (3) dilution. This video is available in the "Related Videos" section of the Full-Text article at PRSGlobalOpen.com or at <http://links.lww.com/PRSGO/A861>.

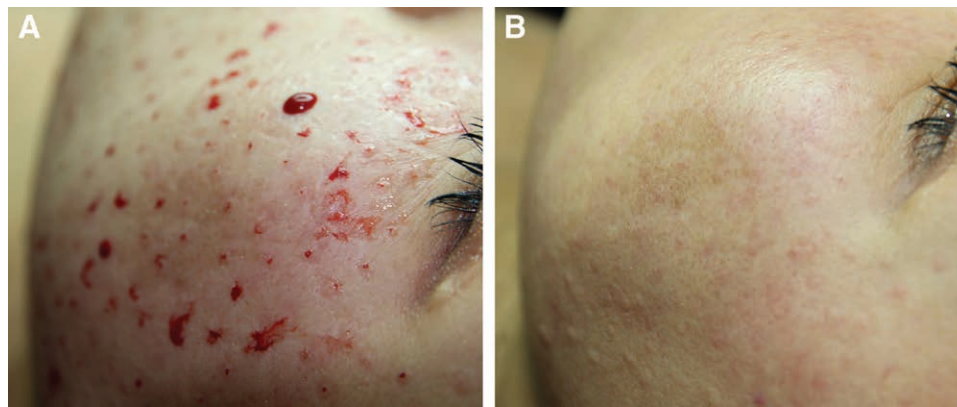


Fig. 1. During the XeoBel hydrotoxin procedure in a 43-year-old woman. A, The small areas of bleeding indicate the optimal depth, intradermis. B, Immediately after 990 injections were made, very small lumps were found, and these lumps disappeared after 1 day.

Measurement of Biophysical Parameters (SCH, TEWL) for Dermal Hydration

Before the biophysical measurements were obtained, patients did not use moisturizers at the measurement day and washed their face with the same cleanser in clinic 30 minutes before the measurements. The patients remained in a comfortable emotional state for 30 minutes at room temperature before taking the measurements to avoid confounding factors. Hydration of the dermis was measured using a noninvasive instrument (gpskin-barrier; gpower, Seoul, Korea). Gpskin simultaneously scans the TEWL and SCH levels of the skin. TEWL and SCH were measured on the forehead and crow's feet area (same areas of dermascope) at 2, 4, and 8 weeks.

Histologic Study of Injected Hyaluronic Acid

Three subjects (38-, 41-, and 45-year-old women) also agreed to allow individual studies with different materials on each side of the face and biopsy samples from the face to be taken on the 28th day after implantation during planned face lifting on the temple area. Polydensified HA was injected on the left side of the face, and biphasic HA (Restylane Vital; Galderma, Uppsala, Sweden) on the right side of the face. The purposes of the biopsy study were (1) to confirm the depth of the deep dermis and to investigate whether an injection technique using an automatic injector for intradermal injection would be successful in terms of providing an even distribution in the deep dermis of the face and (2) to compare the histologic distribution and various features of the collagen fibers displaced by the HA gels after the intradermal injection of polydensified HA and biphasic HA.

RESULTS

Many small lumps were observed in close-up photographs and on dermatoscope at the 990 injection sites immediately after using 3 cc of the XeoBel mixture (Fig. 1), although these lumps disappeared after 1 or 2 days. Microbotox did not disturb facial expressions, and Microhyaluronic acid spread well and did not result in visible lumps. Microbotox and Microhyaluronic acid created vast improve-

ments in fine wrinkles such as the crow's feet and forehead areas (Figs. 2–5) (see figure, **Supplementary Digital Content 2**, which displays the microscopic view; the effect of “Hydrotoxin method” is extraordinary: healthy and smooth skin, improved fine wrinkles, <http://links.lww.com/PRSGO/A862>).

Clinically apparent improvements after 1 session lasted for 6 months in most cases according to measurements of SCH. Subjective improvements in dryness after face-washing were also reported by patients 1 or 2 weeks after the injections, while SCH increased immediately. It may take some time for the material to diffuse into the ECM from the injection site, causing improved feelings of dermal hydration.⁸

Ecchymosis was found after the injections; generally, it lasted for approximately 3 days, although it lasted for 7 days or more in 7 patients (14%) who had thin skin. Thirteen patients (26%) who had relatively thick skin did not suffer from ecchymosis. Ecchymosis could have been due to injections into the subdermis, and this can easily occur when patients have thin skin. The likelihood of subdermal injections was therefore greater in patients with thin skin. However, the improvement of fine wrinkles was greater in patients with thin skin than those with thicker skin. The combination of Microbotox and Microhyaluronic acid was safe from infection, allergy, itching, and inflammation on physical examinations and histologic study.

Dermatoscopic Observations

On microscopic views, skin roughness improved from 3.9 to 1.8 on the forehead and lateral canthus. Fine wrinkles and roughness dramatically improved in the face after the procedure, especially in the crow's feet and forehead areas (Figs. 3–5). All patients experienced improvement of skin roughness after 2, 4, and 8 weeks.

TEWL and SCH

TEWL sensor measures how much water the skin loses. A strong skin barrier keeps moisture in the skin, and a weak barrier does not hold moisture well. The SCH sensor measures how much moisture the skin is holding. TEWL and SCH on the forehead and crow's feet improved (Fig. 6). TEWL and SCH after treatment showed that the barrier function of the skin became stronger,

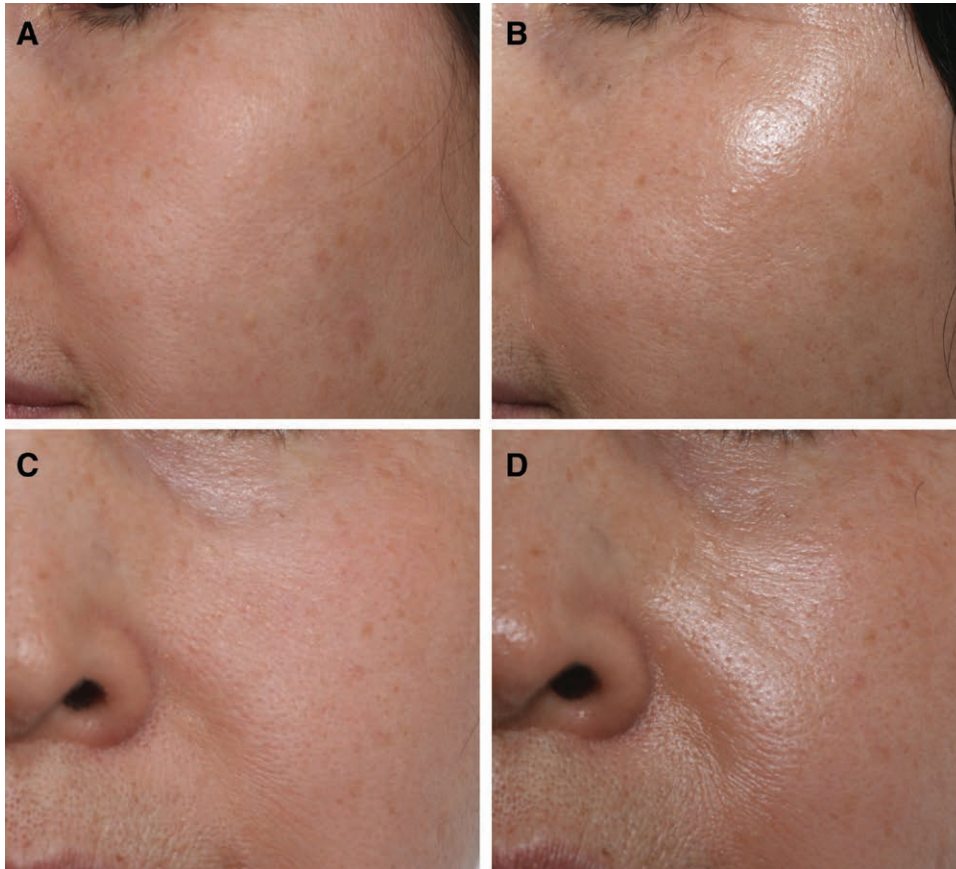


Fig. 2. The hydrotoxin method in a 61-year-old woman. A, C, Before. B, D, 4 weeks after fine wrinkles in the crow's feet area and anterior malar area improved and became shiny.

meaning that skin was retaining more moisture. According to the patients, dryness after face-washing improved, and patients felt less dryness of the skin. The changes between TEWL and SCH on forehead and crow's feet were of statistical significance (paired *t* test < 0.05) at 4 and 8 weeks (Table 1).

Histologic Study of the Injected Hyaluronic Acid in Dermis

- (1) With a 1-mm depth setting on the automatic injector, the actual injection depth on the face was approximately 0.5–0.9 mm because of the bevel of the needle tip.
- (2) On the biopsy study, the polydensified HA was placed with minimal displacement of collagen fibers within the dermis, showing infiltration between collagen fibers. In contrast, the microdroplets of biphasic HA were placed with displacement of collagen fibers within the dermis, showing dermal volumizing effect.
- (3) Dermal thickness was measured from the epidermis to skin appendages. Dermal thickness increased more on the right side of the face, which was injected with biphasic HA, than on the left side.
- (4) There were no inflammatory cells (macrophage, eosinophil, mast cell, plasma cell, and giant cell) around the S-HA on both sides, with polydensified HA (Belotero Balance) on the left side of the face and biphasic HA (Restylane Vital) on the right side of the face (Fig. 7).

DISCUSSION

In manual injections of Microbotox, the injections are delivered into the dermis using insulin syringe with a 30-G needle, raising a tiny blanched wheal at each point, with efforts made to create wheals of the same size/diameter on the dermis. Microbotox refers to the injection of multiple microdroplets of diluted botulinum toxin A into the dermis for skin rejuvenation.⁵ Microbotox can be used to decrease sweat and sebaceous gland activity and to improve skin texture, such as fine wrinkles, or in Neferiti lifting. For treatment of the lower face and neck fold, microdroplets of botulinum toxin improve skin texture, smoothen horizontal creases, and decrease vertical banding of the neck; these effects may be caused by a specific mechanism in the dermis and through paralysis of the platysma muscle.⁵ Microbotox is used to treat various parts of the face (forehead, glabella, the crow's feet area, the infraorbital area, and cheeks) and neck.⁵ The Microbotox technique is easy to learn and administer, with fewer side effects and no unwanted muscle effects.

HA is the main component of the ECM. Intradermal injection of HA has many benefits, such as being safe from embolism, being easy to inject, and leading to more dramatic results on the superficial dermis. A well-hydrated dermis looks healthier, and dermal hydration can help counteract aging of the skin^{1,2}; injection of S-HA can be

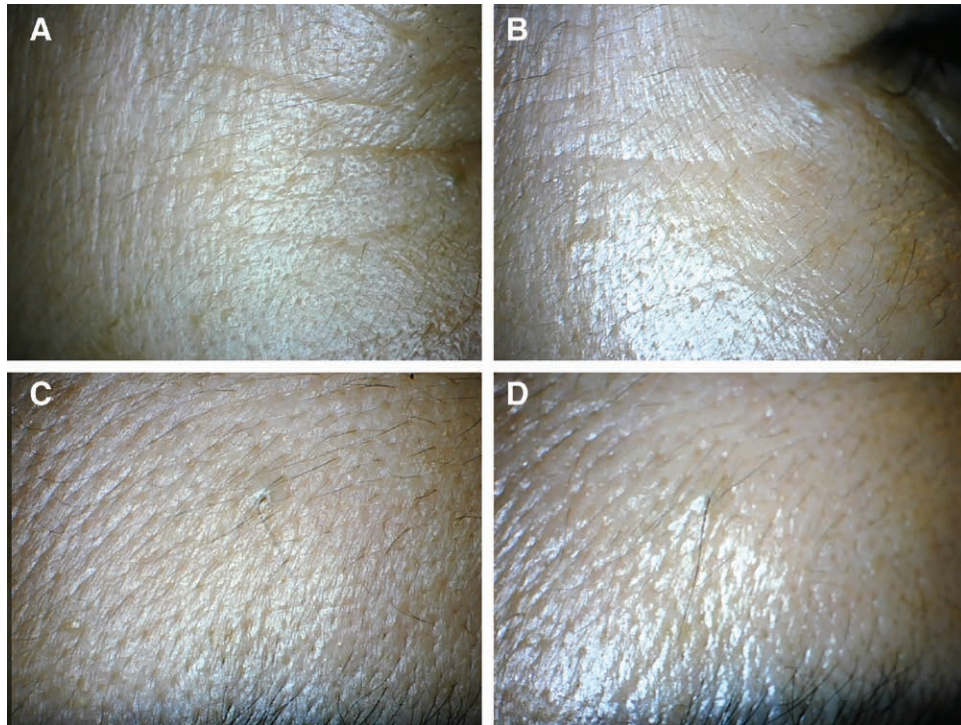


Fig. 3. Dermatoscopic view of the skin of the patient in Figure 2 ($\times 10$ resolution). A, Before treatment on the crow's feet and forehead (C). B, D, 4 weeks after the procedure, fine wrinkles improved and the skin became shiny.

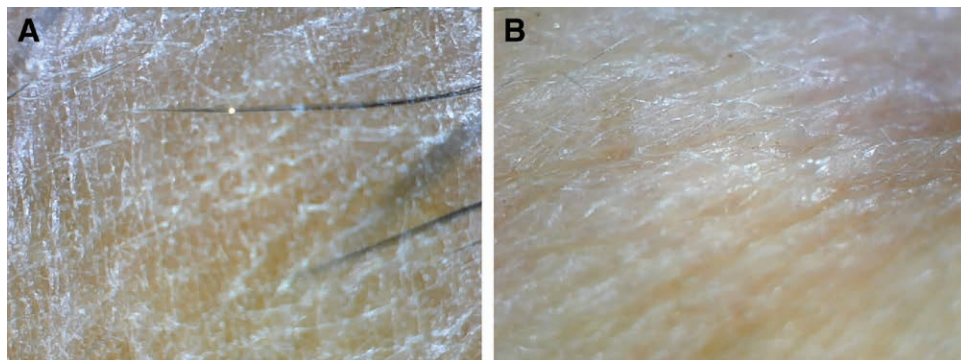


Fig. 4. The crow's feet area of 38-year-old woman who had very dry skin ($\times 50$ resolution). A, Before. B, 4 weeks after the procedure, the skin was hydrated and the fine wrinkles and roughness improved.

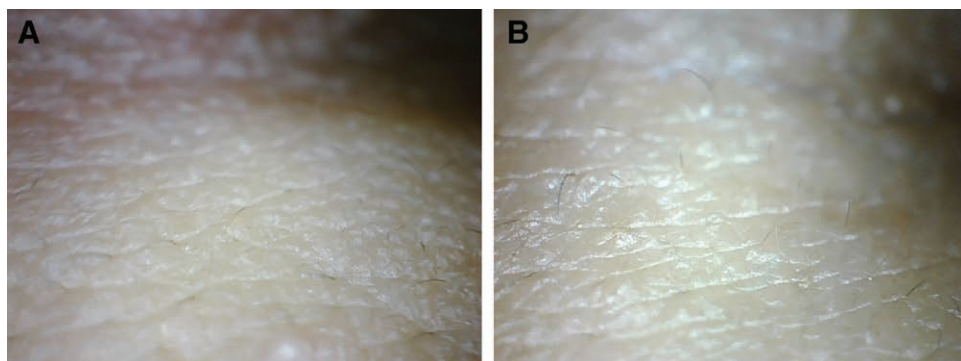


Fig. 5. The crow's feet of 43-year-old ($\times 50$ resolution). A, Before. B, The skin became healthier with hydration 4 weeks after the procedure.

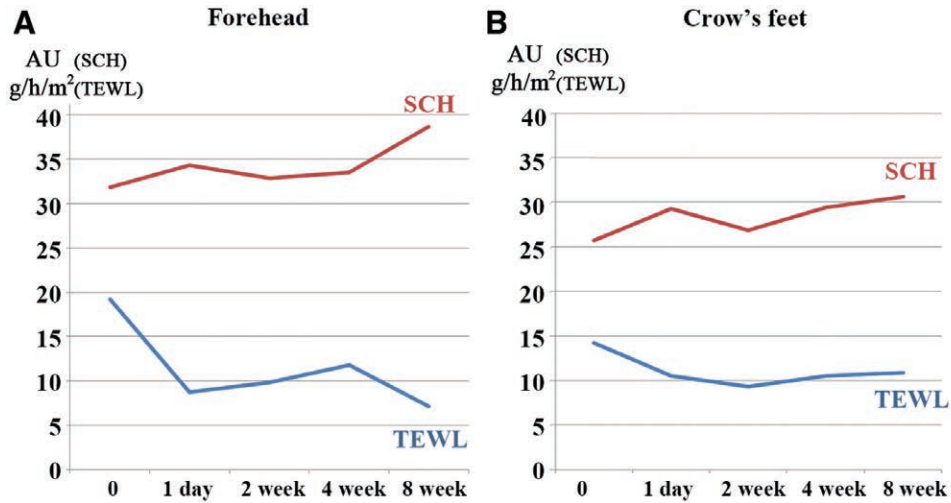


Fig. 6. TEWL and SCH were improved after treatment. AU, arbitrary unit for SCH, g/h/m² (TEWL).

Table 1. Changes in TEWL and SCH

Biophysical parameters	Location	Before	1 d	2 wk	4 wk	8 wk
TEWL	Forehead	19.26±1.41	8.72±2.12	9.80±2.82	11.82±0.70	7.13±2.12
SCH	Crow's feet	31.84±2.82	34.20±2.14	32.88±1.41	33.52±1.41	38.64±7.07
TEWL	Forehead	14.26±6.36	10.54±2.58	9.31±4.24	10.52±2.82	10.80±0.71
SCH	Crow's feet	25.72±4.24	29.22±2.08	26.82±2.82	29.01±0.70	30.66±1.41

TEWL and SCH on the forehead and crow's feet both improved. TEWL and SCH suddenly improved at next day, but these effects might be mainly caused by swelling. TEWL and SCH decreased and improved again slowly. There was statistical significance at 4 and 8 weeks for TEWL and SCH ($P < 0.05$).

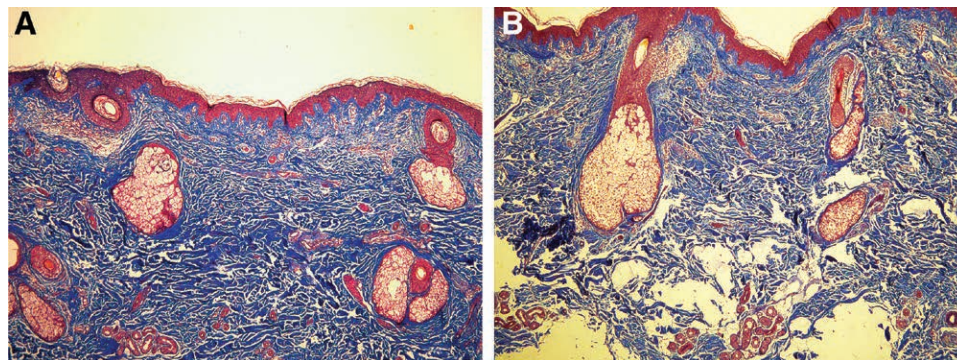


Fig. 7. Histologic images after intradermal injections with Trichrome stain (×40) in a 41-year-old woman. S-HAs were placed between 0.5 and 0.9mm from the epidermis. There were dense stained collagen fibers around S-HA and there was no inflammatory cell. A, Polydensified HA occupied a wider area with relatively even distribution. B, The particles of biphasic HA gathered together without an even distribution in the deep reticular dermis, with displacement of the collagen fibers. Additionally, the dermal thickness from the skin appendages to the epidermis increased, showing dermal volumizing effect.

used to hydrate the dermis at the same time. As we age, the amount of HA associated with collagen and elastin decreases slowly, and the use of realistic replacement ingredients to remediate dermal deficiencies in a safe manner is the goal of HA treatments in most clinics.⁹

With increasing aspirations to treat the skin surface and to rejuvenate the dermis, advancements in hyaluronic acid technology have led to the introduction of new dermal fillers for injection into the dermis, such as Restylane Vital, Belotero Balance, Neuramis light, and Y-solution 360. For

intradermal injections, less reticulated gels with lower concentrations of HA or small-particle HA are often intended to treat fine wrinkles or thin-skin areas such as crow's feet, vertical wrinkles on the upper lip, and the horizontal neck fold. Belotero Balance is produced by 2 cycles of cross-linking with butanediol diglycidyl ether (BDDE), and results in zones of greater and lesser density inside the filler gel.^{10,11} Unlike other S-HA fillers for which the intradermal plane is suggested, a new form of S-HA with a polydensified monophasic HA gel may be more appropriate for the superficial

dermis, because it has a high degree of spreading with lower viscosity, cohesiveness, and elasticity. These properties of S-HA may promote more extensive integration with the dermis, creating more plasticity and reducing the chance of lumps developing in the dermal layer, which is composed of high-density collagen and elastic fibers (Fig. 7). However, these properties have a disadvantage, in that when Belotero Balance is injected into the dermis, it appears to spread inside the dermis and migrate into the subdermis, also without forming nodules or clumps.¹² Therefore, the spreading property of Belotero Balance resulting in less longevity than biphasic HA.¹² Although biphasic HA has greater longevity after intradermal injections, the likelihood of creating lumps may also be greater.² There is no currently available filler with a high degree of spreading and longevity.

Various intradermal injections have been reported, one of the most common methods being the blanching techniques.²⁻⁴ To inject HA into the superficial dermis, the blanching technique was presented by European physicians¹³ in 2011. It has been mentioned in recent articles in the clinical literature,¹⁰ and has been deployed in many clinics over several years, with no consequential adverse events.⁴ With this technique, blanching is caused both by vasoconstriction by the proximity of the transparent gel to the skin's surface; other reasons for blanching techniques success could include tissue distention and blood displacement.^{4,10} To achieve blanching, the amount injected into a single site is too much and causes a lump, which, combined with the above-mentioned reason reduces the appearance of wrinkles. Blanching means that the injection was into the intradermis, and it is a good indication of depth, but it is a less ideal injection method for dermal hydration than automatic injection with microdroplets because of uneven distribution that makes blanching.

When a physician injects S-HA and botulinum toxin separately, it takes more time and is tiresome. Since 2009, when the author's technique was first developed, the author has treated over 2,000 patients with the hydrotoxin method^{1,2} and the author has obtained a patent from the Korean Intellectual Property Office⁶ (see figure, **Supplementary Digital Content 3**, which displays the newspaper from Money Today. My method that we address in this article is a trend in Korea. In the left-bottom picture, Dr. Fravert (developer of Xeomin) visited our hospital to congratulate on the development of XeoBel method, <http://links.lww.com/PRSGO/A863>; see figure, **Supplementary Digital Content 4**, which displays the patent from the Korean Intellectual Property Office. The author has treated over 2,000 patients with the hydrotoxin method, <http://links.lww.com/PRSGO/A864>).

With an automatic injector and the XeoBel mixture, patients felt less pain and the procedure took less time. It was like "killing two birds with one stone." The XeoBel mixture has been used in more than 300 patients in the author's clinic to improve fine wrinkles and dermal hydration. The author's unique combining method of Microbotox and Microhyaluronic acid at 990 injection sites did not result in visible lumps (lumps disappeared when treated by cold compression and the spreading property of HA); it was safe from vascular problems, infection, irritation, and inflammation.

CONCLUSIONS

- (1) The combination of Microbotox (0.04 U) and Microhyaluronic acid (0.001 cc) injected in 990 sites did not create visible lumps and disturb facial expression, and the procedure was very safe from vascular problems and inflammation, confirming it to be a safe method. In histologic study, there were no inflammation cell around S-HA.
- (2) Fine wrinkles on the crow's feet and forehead areas improved after the procedure.
- (3) TEWL and SCH improved after the treatment; the skin became hydrated and healthier with a strong barrier with statistical significance at 4 and 8 weeks.
- (4) With the automatic injector, the actual injection depth on the face was found to range from 0.5 to 0.9 mm in the dermal layer. By using an injector, the time for the procedure involving 990 injection sites can be reduced.

JongSeo Kim, MD

Plastic Surgery Clinic

Seoul, Korea

E-mail: plastic@surgery.co.kr

ACKNOWLEDGMENT

The author expresses his thanks to his Mother (Shin, Choon-Ja) and his hopes for her to get well, with full recovery from lung cancer.

REFERENCES

1. Kim J. *Aesthetic Plastic Surgery of the East Asian Face*. Chapter 30: Facial contouring using fillers. Thieme: New York; 2016:p402.
2. Kim J. Effects of injection depth and volume of stabilized hyaluronic acid in human dermis on skin texture, hydration, and thickness. *Arch Aesthetic Plast Surg*. 2014;20:97-103.
3. Williams S, Tamburic S, Stensvik H, et al. Changes in skin physiology and clinical appearance after microdroplet placement of hyaluronic acid in aging hands. *J Cosmet Dermatol*. 2009;8:216-225.
4. Micheels P. A blanching technique for intradermal injection of the hyaluronic acid Belotero. *Plast Reconstr Surg*. 2013;132:59S-68S.
5. Woffles TL. Microbotox of the lower face and neck: evolution of a personal technique and its clinical effects. *Plast Reconstr Surg*. 2015;136:92S. Microbotox.
6. Title of invention: injection technique using S-HA and automatic injector for dermal hydration and rejuvenation. Patent number: 10-1790405, Certificate of patent of Korean intellectual property office.
7. Tran C, Micheels P, Carraux P, et al. In vivo bio-integration of three HA fillers in human skin: a histology study. *Dermatology* (in press).
8. Amy E, Rose MD, David J, et al. Safety and efficacy of intradermal injection of botulinum toxin for the treatment of oily skin. *Dermatol Surg*. 2013;39:443-448.
9. Farage MA. Characteristics of the aging skin. *Adv Wound Care (New Rochelle)*. 2013;2:5-10.
10. Sundaram H, Flynn T, Cassuto D, et al. New and emerging concepts in soft tissue fillers: roundtable discussion. *J Drugs Dermatol*. 2012;11:s12-s24; discussion s25.
11. Bezzola A, Micheels P. Esthelis acid hyaluronique de conception suisse. Première étude complète des caractéristiques physico-chimiques et essais cliniques. *J Med Esthet Chir Dermatol*. 2005;125:11-20.
12. Flynn TC, Sarazin D, Bezzola A, et al. Comparative histology of intradermal implantation of mono and biphasic hyaluronic acid fillers. *Dermatol Surg*. 2011;37:637-643.
13. Micheels P, Besse S, Flynn TC, et al. Superficial dermal injection of hyaluronic acid soft tissue fillers: comparative ultrasound study. *Dermatol Surg*. 2012;38:1162-1169.